A Case of Recurrent Pelvic Organ Prolapse Treated with Robot-assisted Sacrocolpopexy after Infected Transvaginal Mesh Removal

Hodaka Takeuchi*, Hirofumi Ando, Hisanori Kobara, Masako Nakajima
Manaka Shinagawa, Natsuki Uchiyama, Marina Fujioka and Tsutomu Miyamoto

Department of Obstetrics and Gynecology, Shinshu University School of Medicine

Transvaginal mesh surgery (TVM) for pelvic organ prolapse (POP) has been widely performed, but is associated with mesh-related complications, such as vaginal wall erosion, infection, and abscess formation. We report a case of POP recurrence with mesh infection following posterior TVM surgery (TVM-P), where a favorable outcome was achieved through a two-stage treatment strategy. The patient was a 74-year-old woman with two prior deliveries. Following TVM-P, anterior wall POP recurrence along with infection and abscess formation at the right mesh arm were observed. Conservative treatment was ineffective, and the infected mesh was removed to control the infection. Although no recurrence of the abscess was detected, POP worsened to POP-Q stage 4. Therefore, single-mesh, anterior-wall-only robot-assisted sacrocolpopexy (RSC) was performed. No signs of infection or POP recurrence were noted 6 months postoperatively. While the use of a new mesh is generally contraindicated in cases of mesh infection, this case suggests that staged RSC after successful infection control may be a viable treatment option for recurrent POP. *Shinshu Med J 74 : 279—284, 2026*

(Received for publication April 10, 2026 ; accepted in revised form July 6, 2026)

Key words : pelvic organ prolapse, mesh infection, robot-assisted sacrocolpopexy

Ⅰ Introduction

Transvaginal mesh (TVM) surgery, also known as tension-free vaginal mesh surgery, has been widely adopted as a surgical treatment for pelvic organ prolapse (POP) due to its minimally invasive nature and low recurrence rate **(Fig. 1A)**[1]. However, in recent years, diverse mesh-related complications, such as mesh exposure, infection, abscess formation, pain, and organ injury, have been reported, raising concerns about its safety[2)-8)]. Mesh infection is often resistant to conservative treatment and frequently requires eventual mesh removal. Furthermore, POP recurrence after removal has been reported ; therefore, it is crucial to select the appropriate surgical technique.

* Corresponding author : Hodaka Takeuchi
Department of Obsterics and Gynecology, Shinshu University School of Medicine, 3-1-1 Asahi, Matsumoto, Nagano 390-8621, Japan
E-mail : htakeuchi@shinshu-u.ac.jp

Sacrocolpopexy has recently gained attention due to its low recurrence rate and the advantage of anatomical repair. Furthermore, robot-assisted sacrocolpopexy (RSC) enables minimally invasive and highly precise surgery, allowing accurate anatomical identification and precise suturing in deep pelvic spaces.

We herein report a case where mesh infection and POP recurrence were observed after TVM, staged mesh removal and RSC were required, and a favorable outcome was achieved.

Ⅱ Case

The patient was a 74-year-old woman with two prior deliveries. At age 67, she underwent posterior TVM involving only the posterior vaginal wall at another hospital's Urology Department for POP. Postoperatively, mesh exposure was noted on the posterior vaginal wall, and excision of the exposed mesh was performed on At age 68. In the same year, anterior wall POP recurrence was observed, and the place-

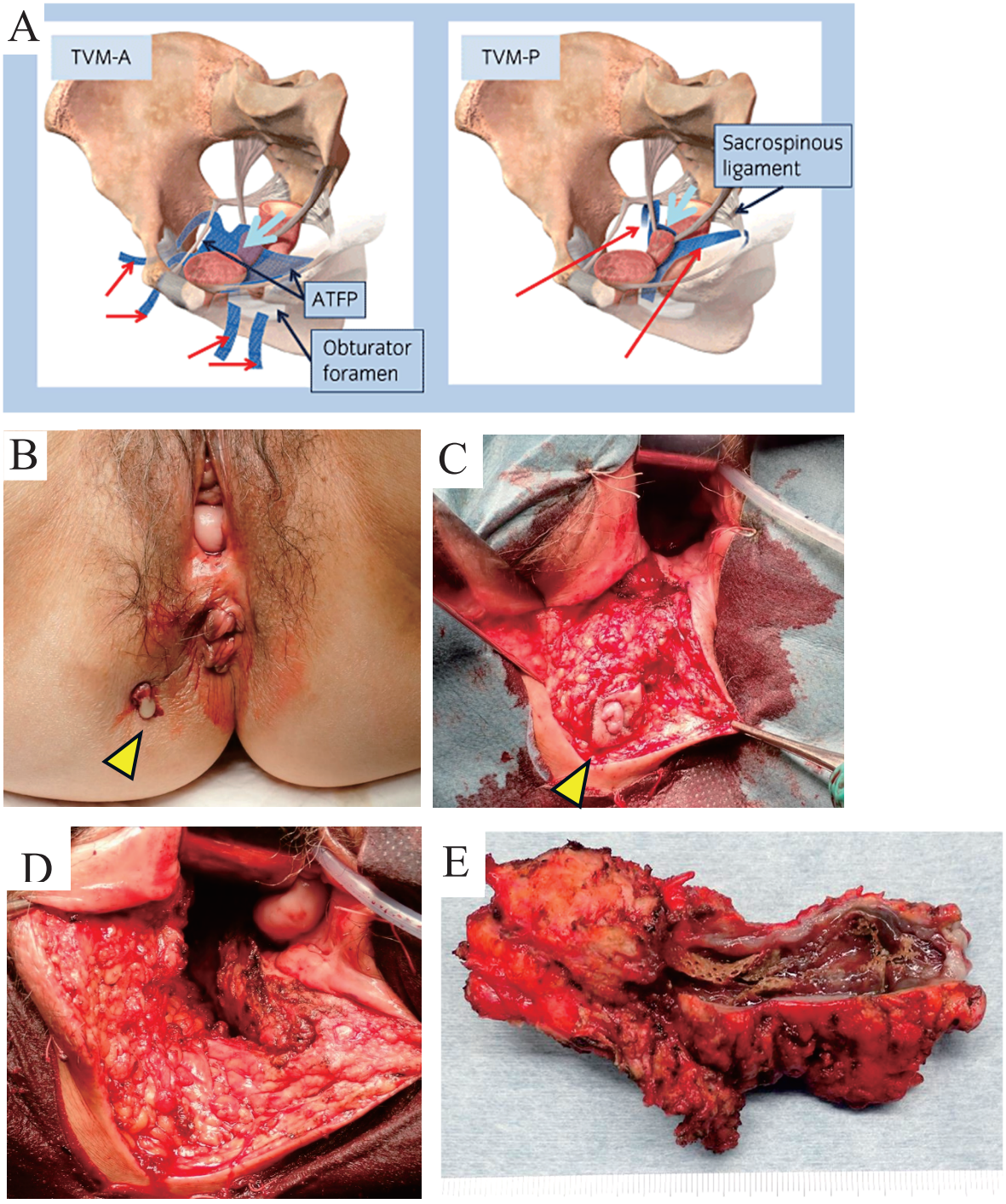

Fig. 1　Surgical Findings from Infected Mesh Removal

A : Sites of mesh fixation in TVM surgery[1)]

B : Skin fistula and purulent discharge (▲) observed on the right buttock.

C : The incision was advanced in a cylindrical manner to avoid exposing the mesh.

D : Post-excision. Partial rupture of the right levator ani muscle was observed.

E : The mesh was confirmed to be continuous from the skin fistula site and was surrounded by necrotic tissue, granulation tissue, and fibrotic tissue.

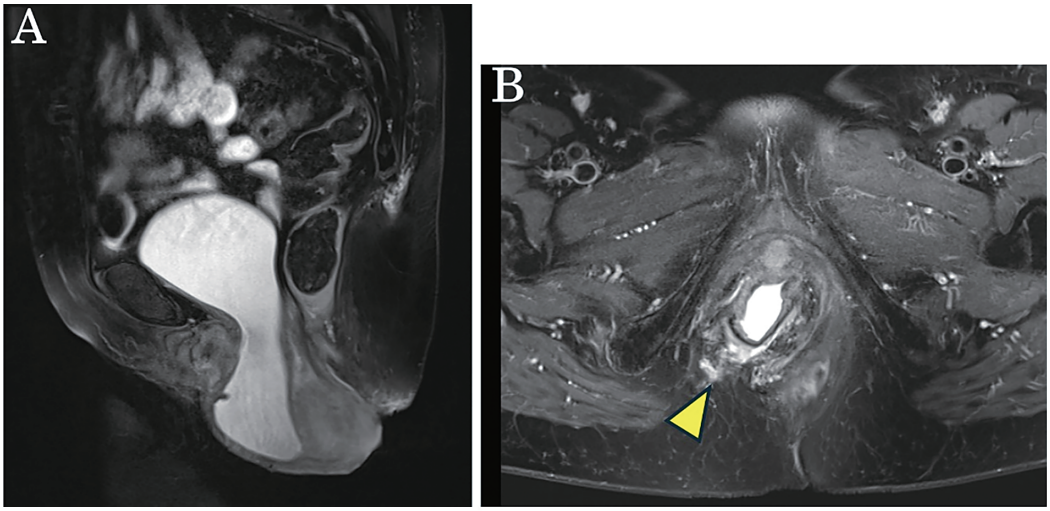

Fig. 2　MRI Findings at POP Recurrence
A : Fat-suppressed T2-weighted sagittal image. POP-Q stage 4 is observed.
B : Fat-suppressed T2-weighted horizontal image. Right levator ani muscle rupture (▲) is observed.

ment of a vaginal pessary was initiated at another hospital's Obstetrics and Gynecology Department. At age 74, she presented to our department with right buttock pain, suspected to be an abscess. An examination revealed POP-Q stage 2, a skin fistula with a purulent discharge on the right buttock, and a painful, firm mass palpable from the mid-posterior vaginal wall to the fistula site. This was diagnosed as infection and abscess of the right mesh arm. Conservative management with antibiotic therapy failed to improve the condition. Therefore, at age 75, after obtaining informed consent from the patient and her family, surgery was performed to remove the infected mesh on the right side.

The procedure was initiated under general anesthesia in the lithotomy position. An incision line was placed from the vaginal opening to the fistula tract. The fistula tract was excised, and the skin was incised with a scalpel. While palpating the mesh and hardened connective tissue due to infection, the incision was advanced circumferentially using an electrosurgical knife. A rectal examination was performed to confirm the position relative to the rectum as the incision progressed. Since the tissue around the levator ani muscle was hard, power sealing was used for cauterization and dissection. The right levator ani muscle was partially torn ; however, the mesh was completely removed without exposure during the process **(Fig. 1B-D)**. The area was thoroughly irrigated with saline. The subcutaneous tissue and skin of the gluteal region were sutured, and the vaginal wound was left open. The procedure was completed. The operative time was 3 hours and 15 minutes, and the estimated blood loss was 510 ml because of severe inflammatory adhesions and fibrosis around the lesion. Postoperatively, wound irrigation and antibiotic therapy were administered. The patient was discharged on the 9th postoperative day. Upon dissection of the excised specimen, the mesh was identified as continuous from the skin fistula site and was surrounded by necrotic tissue, granulation tissue, and fibrotic tissue **(Fig. 1E)**. Pathologically, no malignant findings were observed.

Postoperatively, no recurrence of the abscess was noted ; however, worsening to POP-Q stage 4, characterized by complete vaginal eversion, was noted at age 76 **(Fig. 2)**. Fecal incontinence, furthermore, presumed to be secondary to levator ani muscle rupture, developed. Neither rectal prolapse nor rectocele was observed. Given the residual mesh on the left posterior vaginal wall, native tissue repair was considered to carry a risk of complications, such as infection. Conversely, since no mesh was present on the anterior wall, anterior-wall-only single-mesh RSC was

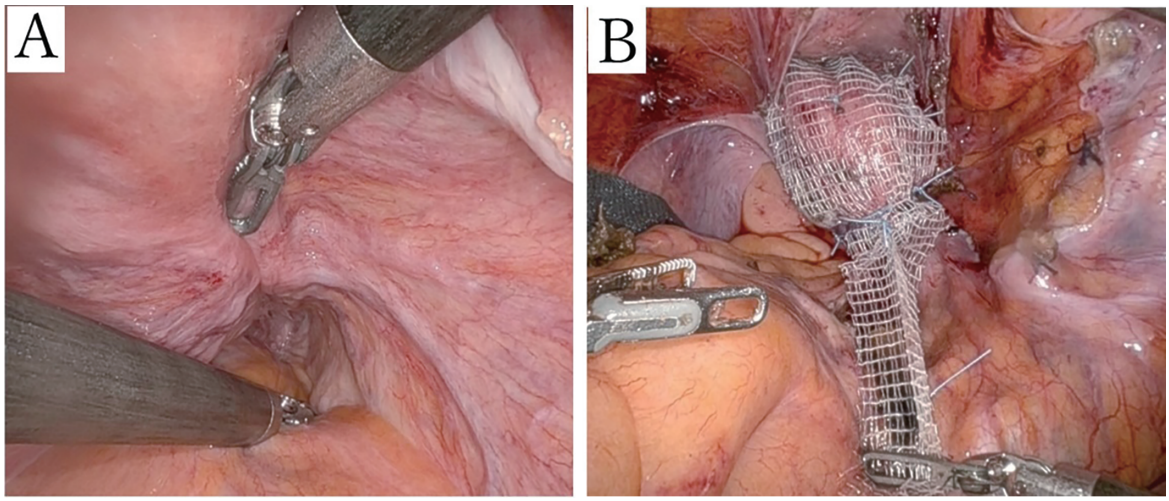

Fig. 3　Surgical Findings of RSC
A : A depression, likely due to the effects of the initial surgery, was observed on the right side of the Douglas pouch.
B : Mesh was fixed to the anterior vaginal wall (anterior mesh fixation), and the posterior wall mesh was fixed laterally, connecting the meshes.

deemed feasible. After obtaining informed consent from the patient and family, anterior-wall-only single-mesh RSC and repair of the ruptured right levator ani muscle were performed.

Surgery was initiated under general anesthesia with the patient in the lithotomy position. The DaVinci Xi robot was used. Port placement consisted of five ports : a 8-mm DaVinci port with Hasson Cone at the umbilicus, 8-mm DaVinci ports 7 cm to the right of the umbilicus and 7 cm lateral to it, and 8 cm to the left of the umbilicus, and a 12-mm assistant port in the left abdomen. A uterine manipulator was inserted. An intra-abdominal examination revealed a depression on the right side of the Douglas pouch, likely due to the effects of infected mesh removal and levator ani muscle rupture **(Fig. 3A)**. The right broad ligament cavity was expanded, the ureter was identified, and the round ligament was isolated and then cauterized and transected. The posterior broad ligament was incised, the round ligament was cauterized and transected, and the peritoneum was incised down to the bladder-uterine pouch. The left side was processed similarly. The vascular bundles, including the ascending branches of the uterine arteries on both sides, were ligated. The uterus was transected at the level of the internal os (supravaginal resection), and the specimen was placed in an EZ pouch®. The stumps were cauterized and closed with 0 Vicryl® Plus sutures. The peritoneum anterior to the promontory was incised, the fascia pre-abdominis was cut, and the anterior longitudinal ligament anterior to the promontory was exposed. A 2-0 Tyclon® suture for mesh fixation was attached to the anterior longitudinal ligament at the promontory. The bladder was dissected from the anterior vaginal wall. The anterior vaginal wall showed no evidence of a mesh-related abscess and was easily dissected from the bladder, allowing sufficient exposure of the anterior vaginal wall up to the Aa point. The mesh was fixed to the anterior vaginal wall (anterior mesh fixation), and subsequently to the posterior cervical wall, designed to reinforce the traction force **(Fig. 3B)**. Due to concerns about a residual left-side mesh or effects from prior abscess treatment, no manipulation was performed from the abdominal side on the posterior wall. The posterior peritoneum of the neck was sutured to the bladder-uterine pouch peritoneal margin, and the mesh was buried. While adjusting tension, the upper edge of the mesh was secured with a suture looped over the promontory. Peritoneal closure was performed, completely burying the mesh, followed by the application of Adspray®. The uterus was retrieved through the umbilical port. The patient was then positioned in the lithotomy position, and transvaginal manipulation commenced. Fol-

lowing vaginal irrigation, epithelialized and granulation tissue areas at the site of the previous incision on the right vaginal wall were excised, exposing the right levator ani muscle stump. The levator ani muscle was repaired using 2-0 Polizorb® sutures. The vagina and perineum were sutured, the vagina was irrigated, and the procedure was completed. The operation time was 5 hours and 55 minutes, with blood loss of 20 ml. The postoperative course was uneventful, and the patient was discharged on the fourth postoperative day. Six months postoperatively, there are no signs of infection, and the recurrence of POP has not been detected. The patient will be followed closely to detect any recurrence of POP.

Ⅲ Discussion

POP is a condition where pelvic organs such as the bladder, uterus, and rectum descend from their normal position. The POP-O staging system is used for its classification. The prevalence of POP stage Ⅱ or higher (where the tip of the prolapsed organ is between −1 and +1 cm from the vaginal opening), which may interfere with daily life, is reportedly 17.1 %. By age group, it is 6.6 % in women in their 20s and 30s, increasing with age to 18.0 % in women in their 60s and 28.7 % in women aged 70 years and older[2].

TVM gained widespread adoption in the 2000s due to its anatomical reinforcement effect. However, serious complications, such as mesh exposure, infection, chronic pain, and abscess formation, have been reported. The attenuation of mesh infection with conservative treatment is often difficult, and mesh removal is frequently required. Mesh-related complications after TVM have been reported in approximately 10-15 % of cases, with infection accounting for about 1-2 %. However, once infection occurs, treatment becomes challenging[3][4]. Benjamin et al. showed that much of the pain and infection associated with TVM originated from the mesh, leading to persistent inflammation[5][6]. In the present case, an abscess formed along the mesh deep within the right buttock, resulting in a skin fistula. Antibiotic therapy was ineffective, necessitating surgical excision. Crosby et al. similarly recommended removal of the entire mesh arm connected to the fistula in cases of mesh infection with fistula formation, as performed in this case's mesh excision surgery[7]. However, they also noted the risk of rectal injury due to fibrosis and adhesions around the levator ani muscle[8]. In the present case, inflammation caused fibrosis severe enough to partially rupture the levator ani muscle.

The rate of recurrence of POP after mesh removal is high at 30-38 %, often necessitating second-stage reconstructive surgery[9][10]. However, in cases with a history of mesh infection, the risk of reinfection with a new mesh is a concern, leading to debate over whether native tissue repair needs to be selected. Previous randomized trials summarized in a Cochrane review reported recurrent prolapse on examination in approximately 38 % of women undergoing native tissue repair[11]. A systematic review by Nazema et al., analyzing 5 RCTs and 8 cohort studies comparing sacrocolpopexy with native tissue repair, suggested that sacrocolpopexy was superior to native tissue repair in preventing recurrence[12]. In the present case, residual mesh remained in the left posterior vaginal wall. Given the presence of residual mesh and the potential risk of infection and recurrent prolapse associated with transvaginal native tissue repair, RSC was selected as the reconstructive procedure.

In the present case, POP-Q stage 4 was presented following the removal of the infected mesh. Due to the presence of residual mesh, conservative managements such as pessary were deemed inappropriate, leading to the decision to pursue surgical intervention. Tissue on the anterior vaginal wall was not affected by TVM or infection, allowing anterior reconstruction with a single mesh. Regarding the posterior wall, the avoidance of laparoscopic manipulation minimized the risk of infection by accounting for residual mesh, scarring, and adhesions. Simultaneously repairing the ruptured levator ani muscle during mesh removal strengthened the supporting structure, which may have contributed to the prevention of recurrence.

Therefore, in cases of POP recurrence with mesh infection following TVM, RSC with new mesh placement is contraindicated. However, as demonstrated in this case, by first removing the infected mesh and

controlling the infection, a staged treatment may be considered. Beyond native tissue repair, RSC may also be a viable treatment option if the mesh fixation site is carefully planned, as performed in the present case.

Ⅳ Conclusion

We herein report a case where two-stage mesh removal followed by RSC improved POP after TVM-associated mesh infection and POP recurrence. If infection may be controlled by removing the infected mesh, as in the present case, performing RSC in a second stage may be a viable treatment option.

Ⅴ Conflict of Interest

There are no conflicts of interest to disclose for the author and all co-authors.

References

1) Masami T : Basic procedures in tension-free vaginal mesh operation for pelvic organ prolapse. Int J Urol 18 : 555-556, 2011
2) Junko K, Chisato N, Kosei M, Naoki I, Ken-Ichirou M : Pelvic organ prolapse and Japanese lifestyle : prevalence and risk factors in Japan. Int Urogynecol J 33 : 47-51, 2022
3) Daniel A, Tapio V, Marie E, Susanne A, Christian Falconer ; Nordic Transvaginal Mesh Group : Anterior colporrhaphy versus transvaginal mesh for pelvic-organ prolapse. N Engl J Med 364 : 1826-1836, 2011
4) Jun K, Satoshi Y, Shingo Y, et al : Risk factors for surgical site infection after transvaginal mesh placement in a nationwide Japanese cohort. Neurourol Urodyn 37 : 1074-1081, 2018
5) Benjamin F, Christopher M : Vaginal mesh contraction : definition, clinical presentation, and management. Obstet Gynecol 115 : 325-330, 2010
6) Chantal MD, Kim WJV, Martijn R, et al : Transvaginal Mesh-related Complications and the Potential Role of Bacterial Colonization : An Exploratory Observational Study. J Minim Invasive Gynecol 30 : 205-215, 2023
7) Andrew B, Cameron H, Joel F, Christian OT : Management of vaginal mesh exposure : A Systematic Review 17 : 40-48, 2019
8) Colby PS, Andre FM, Fatou S, et al : Long-term Outcomes and Complications of Trans-vaginal Mesh Removal : A 14-year Experience. Urology 169 : 70-75, 2022
9) Tanner R, Rebecca SL, Burhan C, Feras A, Philippe EZ : Prolapse Recurrence after Transvaginal Mesh Removal. J Urol 194 : 1342-1347, 2015
10) Andrew B, Elinora P, Michael C, et al : Pain Resolution and Recurrent Prolapse Rates Following Vaginal Mesh Removal. Urology 150 : 134-138, 2021
11) Christopher M, Benjamin F, Kaven B, Corina CS, Nir H, Jane M : Transvaginal mesh or grafts compared with native tissue repair for vaginal prolapse. Cochrane Database Syst Rev. 9 : 2, CD012079, 2016
12) Nazema YS, Cara LG, Elizabeth RC, et al : Mesh sacrocolpopexy compared with native tissue vaginal repair : a systematic review and meta-analysis. Obstet Gynecol 125 : 44-55, 2015

(2026. 4. 10 received ; 2026. 7. 6 accepted)