

## Two Cases of Early Carcinoma of a Reconstructed Gastric Tube after Esophagectomy Treated Extendedly with Endoscopic Submucosal Dissection

Naohiko KOIDE<sup>1)\*</sup>, Akira SUZUKI<sup>1)</sup>, Taiji AKAMATSU<sup>2)</sup>  
and Shinichi MIYAGAWA<sup>1)</sup>

1) *Department of Surgery, Shinshu University School of Medicine*

2) *Department of Gastroenterology, Shinshu University School of Medicine*

We report two cases of gastric tube carcinoma (GTC) treated with endoscopic submucosal dissection (ESD) after esophagectomy. Case 1 was a 47-year-old woman who had received esophagectomy with reconstruction of the gastric tube (GT) for esophageal squamous cell carcinoma. Sixty-seven months later, endoscopy showed a carcinoma in the lower part of the GT. The removed tumor showed a 0-IIc lesion, 10 mm in diameter, diagnosed as a signet ring cell carcinoma limited to the mucosa. Case 2 was an 83-year-old woman who simultaneously underwent lower esophagectomy for basaloid-squamous cell carcinoma of the esophagus and colectomy for ascending colon carcinoma. Sixty-one months later, endoscopy showed a carcinoma in the middle part of the GT. The tumor removed by ESD showed a 0-IIa+IIc lesion, 50 mm in diameter, diagnosed as a moderately differentiated tubular adenocarcinoma limited to the mucosa. The clinicopathologic features of 48 Japanese cases, including Cases 1 and 2, with GTC were reviewed. An extended indication of endoscopic resection for gastric carcinoma was present in 12 (25 %) including Cases 1 and 2. In conclusion, ESD may be safe for GTC; however, further investigations may be necessary to confirm the safety and curative potential of ESD for GTC. *Shinshu Med J 59 : 81–88, 2011*

(Received for publication October 21, 2010; accepted in revised form December 13, 2010)

---

**Key words** : gastric tube, gastric cancer, esophagectomy, endoscopy

---

### I Introduction

Esophageal carcinoma has frequently been associated with other primary carcinomas<sup>1)2)</sup>. Gastric adenocarcinoma is also associated synchronously and/or metachronously with squamous cell carcinoma of the esophagus<sup>3)4)</sup>. The clinical outcome of esophageal carcinoma patients following surgical treatment has recently been improved<sup>5)6)</sup>. In esophageal carcinoma patients treated with surgery, intensive follow-up in order to detect metastasis and recurrence is performed, and long-term follow-up may be necessary. The stomach is frequently

used as a gastric tube (GT) for digestive reconstruction after esophagectomy. Because of the frequent association of gastric carcinoma in patients with esophageal carcinoma, esophagogastroduodenoscopy (EGD) is performed in esophagectomized patients in order to detect carcinoma in the reconstructed GT (GTC).

We herein report two cases of GTC treated with endoscopic submucosal dissection (ESD) after esophagectomy, and review the clinicopathologic features of Japanese cases with GTC treated by endoscopic resection, including polypectomy, endoscopic mucosal resection (EMR) and ESD, reported previously.

### II Case Report

**Case 1** : A 47-year-old woman was admitted for a

---

\* Corresponding author: Naohiko Koide  
Department of Surgery, Shinshu University School of Medicine, 3-1-1, Asahi, Matsumoto-city, Nagano-prefecture, 390-8621, Japan

postoperative health check-up. Sixty-seven months previously, she had undergone esophagectomy via a right thoracotomy with GT reconstruction through the retrosternal route for squamous cell carcinoma of the middle esophagus. The esophageal carcinoma histopathologically invaded the submucosal layer without node metastasis. The patient has received EGD and computed tomography (CT) every year, and has shown a favorable course without any recurrence. Recent EGD showed a slightly depressed lesion (0-IIc type) in the lower part of the

GT (Fig. 1A). Biopsy specimens taken from the lesion histologically showed signet ring cell carcinoma. Abdominal and chest CT showed neither metastasis nor recurrence. This lesion was diagnosed as early GTC. ESD was performed using a hook knife by a gastrointestinal endoscopist. After making marks around the gastric lesion, ESD was started (Fig. 1B). A mucosal incision was performed around the lesion, and the lesion was dissected in the submucosal layer in the usual manner. The tumor was completely removed en-bloc without

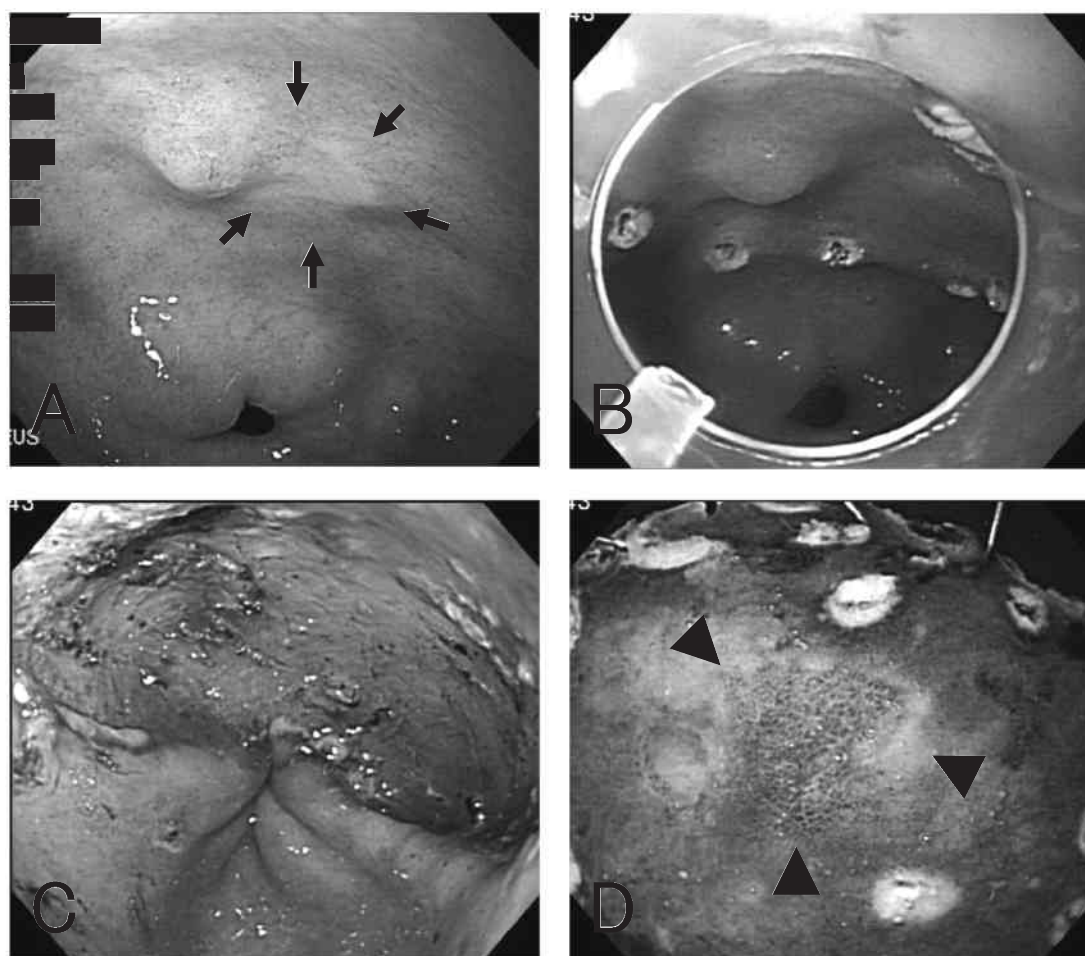


Fig. 1 Endoscopic findings in Case 1

- A : Before endoscopic submucosal dissection (ESD). A slightly depressed mucosal carcinoma (0-IIc type) is observed in the posterior wall of the gastric antrum (arrowheads). Although biopsy specimens taken from the tumor showed signet ring cell carcinoma, those taken from 1 cm away from the tumor histologically showed no carcinoma cell employing AB-PAS as well as HE staining.
- B : ESD was started after making some marks around the tumor.
- C : After ESD. The tumor is completely removed by ESD, and neither perforation nor hemorrhage is observed.
- D : An endoscopically resected specimen. In the center of the ESD specimen, the slightly depressed lesion is observed with a finely defined horizontal margin.

massive hemorrhage and perforation (Fig. 1C). The removed tumor macroscopically showed a 0-IIc lesion (Fig. 1D). Histopathologic examination demonstrated signet ring cell carcinoma, 10 mm in diameter, limited to the mucosa without lymphatic and venous invasion of the carcinoma cells. The lateral and vertical margins were negative for carcinoma cells. The patient is currently well without any metastasis or recurrence of GTC 41 months after ESD.

**Case 2:** An 83-year-old woman was admitted for a postoperative health check-up. Sixty-one months previously, she had simultaneously undergone surgery for carcinomas of the esophagus and colon. Basaloid-squamous cell carcinoma of the lower esophagus, histopathologically invading the submucosal layer without node metastasis, was removed by a lower esophagectomy with proximal gastrectomy via a wide incision of the diaphragm from the esophageal hiatus. A GT was constructed preserving the right gastric and gastroepiploic arteries. The digestive tract was reconstructed by esophagegastrostomy using a circular stapler instrument in the mediastinum through the esophageal hiatus. Furthermore, adenocarcinoma of the ascending colon, histopathologically invading the submucosal layer without node metastasis, was synchronously removed employing a right colectomy. The patient has received EGD, colonoscopy, and CT of the chest and abdomen every year, and remained well without any recurrence over the last year. The last EGD showed a protruding lesion with a depression (0-IIa+IIc type) in the middle part of the lesser curvature of the GT. Biopsy specimens taken from the lesion histologically showed moderately differentiated tubular adenocarcinoma. Abdominal and chest CT showed neither metastasis nor recurrence. This lesion was diagnosed as early GTC. ESD was performed using a hook knife, and the lesion was completely removed en-bloc without massive hemorrhage or perforation. The removed tumor macroscopically showed a 0-IIa+IIc lesion with a well-defined margin. Histopathologic examination showed a

moderately differentiated tubular adenocarcinoma, 50 mm in diameter, limited to the mucosa; however, lymphatic invasion of the carcinoma cells was observed. The patient is well without any metastasis or recurrence of GTC 12 months after ESD.

### III Discussion

GTC was observed in approximately 1-2% of patients with surgery for esophageal carcinoma<sup>4)7)</sup>. The presence of synchronous or metachronous gastric carcinoma is an issue in the management and treatment of patients with esophageal carcinoma. Recently, the clinical outcome of patients with esophageal carcinoma who have undergone curative esophagectomy with extended node dissections has been improved, and a second primary carcinoma after esophagectomy is noted in these long-term follow-ups<sup>1)2)</sup>. These carcinomas arising from the reconstructed stomach after esophagectomy have sometimes been reported in Japan, but have rarely been reported in Western countries. The present two cases showed a superficial type limited to the submucosal layer of the esophagus, and their clinical outcome was favorable after previous surgery. Long-term follow-up with EGD is necessary for the detection of GT disorders after curative surgery for esophageal cancer.

EMR and ESD have been widely employed for early gastric carcinoma, especially mucosal carcinoma that is both well and moderately differentiated. In spite of the limitation of curative endoscopic resection of early gastric carcinoma, the prognosis of patients with early gastric carcinoma treated by ESD is likely to be excellent<sup>8)</sup>. A consensus regarding the safety and curative potential of endoscopic treatments for GTC has yet to be reached. However, in esophagectomized patients, additional gastrectomy involves several issues regarding operative procedures and postoperative complications<sup>4)</sup>. In Case 2, although the tumor size was 5 cm in diameter, en-bloc resection without massive hemorrhage or perforation of the GT was safely and completely performed by ESD. Furthermore, well-differentiated adenocarcinoma limited to the

mucosa showed lymphatic invasion after ESD. The elderly patient requested no further treatment, including surgery and chemotherapy. Case 1 showed signet ring cell carcinoma of the GT, but the horizontal and vertical margins were histologically negative. Endoscopic treatment has been controversial for signet ring cell carcinoma or poorly differentiated adenocarcinoma of the stomach, but mucosal undifferentiated cancer without ulcer findings and smaller than 20 mm in size showed no node metastasis<sup>9)</sup>. ESD has gradually become available for specific histologic types, as an extended indication of endoscopic resection for early gastric carcinoma. Signet ring cell carcinoma, which has rarely been observed in the GT, treated by EMR or ESD has been reported in 2 Japanese cases<sup>10)11)</sup> and the present Case 1. These three cases underwent no additional treatment. ESD may have more advantages than surgery for the treatment of early GTC. The gastric tube is located in the mediastinum or thoracic cavity, and this reconstructed stomach shows a narrow cavity compared to the usual stomach. It may therefore be a special condition for ESD of gastric carcinoma. Further investigation involving a large-scale study is necessary to assess the safety and curative potential of ESD for GTC after surgery for esophageal carcinoma, although recent case series regarding ESD for GTC have been reported<sup>12)</sup>.

We investigated the clinicopathologic features of 48 Japanese cases<sup>7)10)–36)</sup>, including the two present patients, with GTC in which the histopathologic findings were described in detail in papers published between 1983 and 2009, as retrieved from PubMed and Japana Centra Revo Medicina (Table 1). Most of the previously reported cases were treated by EMR. GTC removed by ESD was observed in 10 cases including the present 2 cases. Most of the reported cases showed a tumor size of less than 20 mm in diameter, while 4 cases (8.3 %) showed a tumor size of over 20 mm in diameter, including Case 2. Most of the reported cases showed well-

differentiated adenocarcinoma, such as in Case 2, while signet ring cell carcinoma was observed in only 3 cases (6.3 %), including Case 1. Most of the reported cases showed mucosal cancer, but submucosal cancer was observed in 5 cases (10.4 %). Consequently, extended indications of endoscopic treatment for gastric carcinoma were available in 12 cases (25 %), including the 2 present cases. Within 24 months after esophagectomy, 13 cases (27.1 %) showed GTC, and 20 cases (41.7 %), including Cases 1 and 2, showed GTC over 60 months after esophagectomy. Therefore, before and after esophagectomy for esophageal cancer, the stomach should be carefully examined by EGD. When an endoscope can not pass through esophageal cancer, we have to manage and examine the stomach during the operation and after surgery<sup>3)</sup>. Local recurrence or insufficient resection was observed in 12 cases (25 %) with additional treatments after EMR. Additional treatment including EMR<sup>27)29)32)</sup>, endoscopic laser treatment<sup>19)25)</sup> or endoscopic coagulation/ablation treatment<sup>17)27)33)35)</sup>, and gastrectomy<sup>11)28)31)</sup> were performed in cases with incomplete resection by EMR or the local recurrence of GTC after EMR. ESD is an option to treat early GTC.

In conclusion, ESD is a safe modality for mucosal carcinoma of the reconstructed GT, and ESD may be available for cases with extended indications, such as the present cases. However further investigation is necessary to confirm the safety and curative potential of ESD for large well-differentiated adenocarcinoma or signet ring cell carcinoma of the GT after surgery for esophageal carcinoma.

#### Acknowledgements

We gratefully acknowledge the large contributions to this article by Dr. Tomoaki Suga (Department of Gastroenterology, Shinshu University School of Medicine) and Dr. Takai Kuroda (Jinai Hospital).

ESD for carcinoma of the gastric tube

Table 1 Japanese cases of gastric tube carcinoma treated by endoscopic resection

| Case | Author    | Year | Age/Sex | Interval (months) | Treatment | Features of gastric tube carcinoma |           |           |           |       | Additional treatment |
|------|-----------|------|---------|-------------------|-----------|------------------------------------|-----------|-----------|-----------|-------|----------------------|
|      |           |      |         |                   |           | Site                               | Size (mm) | Type      | Histology | Depth |                      |
| 1    | Hirano    | 1988 | 73/M    | 118               | PE        | lower                              | ?         | 0-I       | tub1      | ?     | CT                   |
| 2    | Monma     | 1989 | 71/M    | 18                | EMR       | middle                             | 12×12     | 0-IIa     | tub1      | m     |                      |
| 3    | Monma     | 1989 | 78/M    | 72                | EMR       | lower                              | 8×7       | 0-IIa+IIc | tub1      | m     |                      |
| 4    | Watanabe  | 1991 | 89/F    | 54                | EMR       | lower                              | ?         | 0-IIa+IIc | tub1      | m     |                      |
| 5    | Miyoshi   | 1992 | 63/M    | 38                | EMR       | middle                             | 6×8       | 0-IIa     | tub1      | m     |                      |
| 6    | Nakata    | 1993 | 65/F    | 84                | EMR       | lower                              | 15×10     | 0-I       | tub1      | sm    | HLC/EI               |
| 7    | Fukushima | 1993 | 64/M    | 120               | PE        | upper                              | 20×7      | 0-I       | pap       | m     |                      |
| 8    | Sato      | 1994 | 78/M    | 54                | EMR       | lower                              | 12×10     | 0-IIa     | tub1      | m     | Laser                |
|      |           |      |         |                   | EMR       | middle                             | 7         | 0-IIc     | tub1      | m     | Laser                |
| 9    | Shimada   | 1998 | 57/F    | 78                | EMR       | lower                              | ?         | 0-IIc     | tub1      | m     |                      |
| 10   | Shimada   | 1998 | 81/M    | 153               | EMR       | lower                              | ?         | 0-IIa     | tub1      | m     |                      |
| 11   | Shimada   | 1998 | 76/M    | 21                | EMR       | ?                                  | ?         | 0-IIc     | ?         | m     |                      |
| 12   | Hanashi   | 1998 | 71/M    | 21                | EMR       | middle                             | 12×12     | 0-IIa     | tub1      | m     |                      |
| 13   | Hanashi   | 1998 | 78/M    | 72                | EMR       | lower                              | 8×7       | 0-IIa+IIc | tub1      | m     |                      |
| 14   | Ishida    | 1998 | 78/?    | 132               | EMR       | lower                              | ?         | 0-IIc     | tub1      | m     |                      |
| 15   | Song      | 1998 | 54/M    | 24                | EMR       | middle                             | 6         | 0-I       | ?         | m     |                      |
| 16   | Hase      | 2000 | 83/F    | 165               | EMR       | upper                              | 25        | 0-IIa     | tub1      | m     |                      |
| 17   | Sekita    | 2001 | 60/M    | 47                | EMR       | middle                             | 20        | 0-IIa+IIc | tub1      | m     | Laser                |
|      |           |      |         |                   | EMR       | lower                              | 15        | 0-IIc     | tub1      | m     |                      |
|      |           |      |         |                   | EMR       | lower                              | 10        | 0-IIc     | tub1      | m     |                      |
| 18   | Suzuki    | 2001 | 60/M    | 11                | EMR       | lower                              | ?         | 0-?       | tub1      | ?     |                      |
| 19   | Nakai     | 2002 | 71/M    | 20                | EMR       | middle                             | 10        | 0-IIa     | tub1      | m     | EMR/AB               |
| 20   | Kawamoto  | 2002 | 63/M    | 24                | EMR       | lower                              | ?         | 0-III     | tub2      | sm2   | Gastrectomy          |
| 21   | Hamasu    | 2003 | 68/M    | 20                | EMR       | lower                              | 16        | 0-I       | well      | m     | EMR                  |
| 22   | Matsuda   | 2003 | 56/M    | 38                | EMR       | lower                              | 20×13     | 0-IIa     | tub1      | m     |                      |
| 23   | Okamoto   | 2004 | 72/M    | 30                | EMR       | lower                              | < 10      | ?         | well      | m     |                      |
| 24   | Okamoto   | 2004 | 66/M    | 221               | EMR       | middle                             | ?         | ?         | mod       | sm    |                      |
| 25   | Okamoto   | 2004 | 59/M    | 39                | EMR       | middle                             | < 10      | ?         | well      | m     |                      |
| 26   | Suganuma  | 2004 | 63/M    | 86                | EMR       | lower                              | 7         | 0-IIa     | tub1      | m     | Gastrectomy          |
| 27   | Tanaka    | 2004 | 71/M    | 72                | EMR       | middle                             | 10        | 0-IIc     | tub1      | m     | EMR                  |
|      |           |      |         | 78                | EMR       | lower                              | 5         | 0-IIc     | tub1      | m     |                      |
| 28   | Tasaki    | 2006 | 50/M    | 43                | EMR       | lower                              | 10×8      | 0-IIb     | sig       | m     |                      |
| 29   | Takeo     | 2007 | 63/M    | 74                | EMR       | lower                              | 6         | 0-IIa     | tub1      | m     | Gastrectomy          |
| 30   | Takeo     | 2007 | 57/M    | 28                | EMR       | middle                             | 3         | 0-IIc     | tub1      | m     |                      |
|      |           |      |         | 43                | EMR       | middle                             | 6         | 0-IIa     | pap       | m     |                      |
| 31   | Takeo     | 2007 | 70/M    | 62                | EMR       | middle                             | 12        | 0-IIc     | tub2      | m     |                      |
| 32   | Takeo     | 2007 | 58/M    | 15                | EMR       | lower                              | 6         | 0-IIc     | sig       | m     |                      |
| 33   | Takeo     | 2007 | 69/M    | 12                | EMR       | lower                              | 15        | 0-IIa+IIc | tub1      | m     |                      |
| 34   | Motoyama  | 2007 | 70s/M   | 33                | EMR       | middle                             | ?         | 0-IIa+IIc | ?         | sm    | APC/RT/CT            |
| 35   | Yamasawa  | 2009 | 75/M    | 15                | EMR       | ?                                  | ?         | 0-IIa     | tub1      | ?     |                      |
| 36   | Yamasawa  | 2009 | 61/M    | 76                | EMR       | ?                                  | 15        | 0-IIa     | tub1      | m     |                      |
| 37   | Yamasawa  | 2009 | 75/M    | 104               | ESD       | middle                             | 60×40     | 0-IIa     | tub1      | m     |                      |
| 38   | Koyanagi  | 2009 | 70s/M   | 78                | EMR       | middle                             | 15        | 0-IIc     | tub2      | m     | APC                  |
| 39   | Suzumura  | 2009 | 62/F    | 42                | EMR       | lower                              | 5         | 0-IIc     | tub1      | m     |                      |
| 40   | Osumi     | 2009 | 50s/M   | 26                | ESD       | middle                             | 20×15     | 0-IIa     | pap       | m     |                      |
| 41   | Osumi     | 2009 | 60s/M   | 19                | ESD       | middle                             | 11×7      | 0-IIc     | tub1      | m     |                      |
| 42   | Osumi     | 2009 | 80s/M   | 55                | ESD       | lower                              | 12.8×11.8 | 0-IIa     | tub1      | m     |                      |
| 43   | Osumi     | 2009 | 80s/F   | 12                | ESD       | middle                             | 15.2×13.1 | 0-IIa     | tub1      | m     |                      |
|      |           |      |         |                   |           | middle                             | 11.2×9.8  | 0-IIa     | tub1      | m     |                      |
| 44   | Osumi     | 2009 | 80s/M   | 42                | ESD       | middle                             | 30×17.5   | 0-IIa+IIc | tub1      | m     |                      |
| 45   | Osumi     | 2009 | 70s/M   | 26                | ESD       | middle                             | 12.8×11.8 | 0-IIa+IIc | tub1      | sm2   |                      |
| 46   | Osumi     | 2009 | 60s/M   | 31                | ESD       | lower                              | 14.8×7.9  | 0-IIa     | tub1      | m     |                      |
| 47   | Case 1    |      | 47/F    | 67                | ESD       | lower                              | 10        | 0-IIc     | sig       | m     |                      |
| 48   | Case 2    |      | 83/F    | 61                | ESD       | middle                             | 50        | 0-IIa+IIc | tub2      | m     |                      |

Interval, between esophageal carcinoma treatment and detection of gastric tube carcinoma ;  
 PE, polypectomy ; EMR, endoscopic mucosal resection ; ESD, endoscopic submucosal dissection ;  
 tub1, well-differentiated tubular adenocarcinoma ; tub2, moderately differentiated adenocarcinoma ;  
 pap, papillary adenocarcinoma ; sig, signet ring cell carcinoma ;  
 CT, chemotherapy ; HLC, heat lobe coagulation ; EI, ethanol injection ; AB, ablation ;  
 APC, argon plasma coagulation ; RT, radiotherapy ; ?, not described.

## References

- 1) Koide N, Yazawa K, Koike S, Adachi W, Amano J : Oesophageal cancer associated with other primary cancers : a study of 31 patients. *J Gastroenterol Hepatol* 12 : 690-694, 1997
- 2) Matsubara T, Yamada K, Nakagawa A : Risk of second primary malignancy after esophagectomy for squamous cell carcinoma of the thoracic esophagus. *J Clin Oncol* 21 : 4336-4341, 2003
- 3) Koide N, Adachi W, Koike S, Watanabe H, Yazawa K, Amano J : Synchronous gastric tumors associated with esophageal cancer : a retrospective study of twenty-four patients. *Am J Gastroenterol* 93 : 758-762, 1998
- 4) Sugiura T, Kato H, Tachimori Y, Igaki H, Yamaguchi H, Nakanishi Y : Second primary carcinoma in the gastric tube constructed as an esophageal substitute after esophagectomy. *J Am Coll Surg* 194 : 578-583, 2002
- 5) Ando N, Ozawa S, Kitagawa Y, Shinozawa Y, Kitajima M : Improvement in the results of surgical treatment of advanced squamous esophageal carcinoma during 15 consecutive years. *Ann Surg* 232 : 225-232, 2000
- 6) Morita M, Yoshida R, Ikeda K, Egashira A, Oki E, Sadanaga N, Kakeji Y, Yamanaka T, Maehara Y : Advances in esophageal cancer surgery in Japan : an analysis of 1000 consecutive patients treated at a single institute. *Surgery* 143 : 499-508, 2008
- 7) Okamoto N, Ozawa S, Kitagawa Y, Shimizu Y, Kitajima M : Metachronous gastric carcinoma from a gastric tube after radical surgery for esophageal carcinoma. *Ann Thorac Surg* 77 : 1189-1192, 2004
- 8) Isomoto H, Shikuwa S, Yamaguchi N, Fukuba E, Ikeda K, Nishiyama H, Ohnita K, Mizuta Y, Shiozawa J, Kohno S : Endoscopic submucosal dissection for early gastric cancer : a large-scale feasibility study. *Gut* 58 : 331-336, 2009
- 9) Gotoda T, Yanagisawa A, Sasako M, Ono H, Nakanishi Y, Shimoda T, Kato Y : Incidence of lymph node metastasis from early gastric cancer : estimation with a large number of cases at two large centers. *Gastric Cancer* 3 : 219-225, 2000
- 10) Tasaki K, Ooshima I, Yoshimura S, Okazaki Y, Kakuta Y : A case report of gastric tube cancer after esophageal cancer radical operation treated by endoscopic mucosal resection (in Japanese with English abstract). *Gastroenterol Endosc* 48 : 310-315, 2006
- 11) Takeo H, Matsukura S : Gastric tube cancer : immunohistochemical study of 10 lesions in six patients. *J Gastroenterol Hepatol* 22 : 23-29, 2007
- 12) Osumi W, Fujita Y, Hiramatsu M, Kawai M, Sumiyoshi K, Umegaki E, Tokioka S, Yoda Y, Egashira Y, Abe S, Higuchi K, Tanigawa N : Endoscopic submucosal dissection allows less-invasive curative resection for gastric tube cancer after esophagectomy - a case series. *Endoscopy* 41 : 777-780, 2009
- 13) Hirano H, Abo H, Hashimoto M, Miyake M, Yamazaki Y, Toma H : Two cases of carcinoma of the reconstructed gastric tube after surgery for esophageal cancer (in Japanese). *Akita Med J (Akitaken Ishikai Zasshi)* 40 : 146-148, 1988
- 14) Monma K, Sakaki N, Saeki S, Yamamoto M, Murata Y, Yoshida M : Endoscopic therapy for early gastric carcinoma in the reconstructed stomach tube after radical operation of esophageal carcinoma (in Japanese with English abstract). *Prog Dig Endosc (Shokaki Naisikyo no Shinpo)* 35 : 268-271, 1989
- 15) Watanabe T, Sato H, Hattori Y, Kamibayashi S, Kojima M : A case of early gastric cancer in the reconstructed gastric tube after operation for esophageal cancer (in Japanese with English abstract). *Kyosai Med J (Kyosai Iho)* 41 : 505-509, 1991
- 16) Miyoshi H, Shikata J, Togura Y : A case of acute gastric mucosal bleeding and early gastric cancer in the reconstructed stomach tube after operation of esophageal cancer (in Japanese with English abstract). *Gastroenterol Endosc* 34 : 555-560, 1992
- 17) Nakata H, Ito S, Yokoya Y, Kawai J, Kawaguchi S, Yamanishi T, Hara T, Nakata H, Sakatsuji K, Nishioka S :

- A endoscopically resected case of early gastric carcinoma developed in the reconstructed stomach tube (in Japanese with English abstract). *Gastroenterol Endosc* 35 : 2166-2171, 1993
- 18) Fukushima W, Yagi M, Sakamoto K, Ii T, Shimizu K, Yonemura Y, Izumi R, Miwa K, Miyazaki I : A report of early cancer of the reconstructed gastric tube after radical resection for early esophageal cancer (in Japanese with English abstract). *Jpn J Gastroenterol Surg (Nihon Shokaki Geka Gakkai Zasshi)* 26 : 2185-2188, 1993
  - 19) Sato E, Kawasaki T, Otsukasa S, Jibiki M, Aoi T, Nosaka T, Ueda Y, Kikuchi M, Endo M, Nakazawa Y : A case of double early gastric cancers in the reconstructed stomach tube about 4 years 6 months after radical operation for synchronous double carcinoma of the esophagus and the stomach (in Japanese with English abstract). *Prog Dig Endosc* 44 : 114-118, 1994
  - 20) Shimada H, Chino O, Nishi T, Tanaka H, Oshiba G, Himeno N, Kenmochi T, Machimura T, Tajima T, Makuuchi H : Gastric cancer in the reconstructed gastric roll (in Japanese with English abstract). *Endosc Dig (Shokaki Naishikyo)* 10 : 51-57, 1998
  - 21) Hanashi T, Yoshida M, Monma K, Katou H, Sakaki N, Koike M : A case of carcinoma in the gastric tube used as an esophageal substitute : early gastric cancer treated by endoscopic mucosal resection (in Japanese with English abstract). *Endosc Dig (Shokaki Naishikyo)* 10 : 83-86, 1998
  - 22) Ishida K, Sugawara M, Saito K, Sato S : Early gastric cancer and peptic ulcer in the gastric roll after esophagectomy (in Japanese with English abstract). *Endosc Dig (Shokaki Naishikyo)* 10 : 87-89, 1998
  - 23) Song K, Sato H, Maruyama I, Suzuki T, Otsuka Y, Yamagata M, Fukase T, Kobayashi H, Inami N, Iwai S : Clinical study on 96 cases of esophageal cancer associated with other primary cancers (in Japanese). *JJSC (Nihon Gekakei Rengo Gakkaishi)* 23 : 910-913, 1998
  - 24) Hase R, Numata A, Taira K, Nenohi M, Ito N, Kato H : Three cases of the stomach tube following operation for cancer of the thoracic esophagus (in Japanese with English abstract). *J Jpn Surg Assoc (Nihon Rinshogeka Gakkai Zasshi)* 61 : 1770-1774, 2000
  - 25) Sekita Y, Takeshita K, Tani M, Kaisan T, Inoue H, Honda T, Saito N, Iwai T, Nagai K : An endoscopically treated case of multiple early gastric cancers in the reconstructed stomach after esophagectomy (in Japanese with English abstract). *Prog Dig Endosc* 58 : 84-85, 2001
  - 26) Suzuki H, Kitamura M, Saito R, Motoyama S, Ogawa J : Cancer of the gastric tube reconstructed through the posterior mediastinal route after radical surgery for esophageal cancer. *JJTCVS* 2001 49 : 466-469, 2001
  - 27) Nakai M, Shiroko J, Shiroko T, Goto N, Hashiyama N, Ohnishi T, Asano H, Tanabashi S, Kametani M, Okamoto K : Two cases of carcinoma in the gastric tube after esophagectomy for esophageal cancer -the clinical examination of the report in Japan- (in Japanese). *Jpn J Gastroenterol (Nippon Shokakibyō Gakkai Zasshi)* 99 : 789-797, 2002
  - 28) Kawamoto K, Okamoto T, Takagi H, Fujiki M, Ikeda H, Makino T, Moriga T, Niwano M, Sano K, Ooshio G, Yoshida Y, Itoh T, Ogasahara K, Takasan H : A case of carcinoma in the reconstructed gastric tube after radical resection for esophageal cancer (in Japanese with English abstract). *Ann Kurashiki Cent Hosp (Kurashiki Chuo Byoin Nenpo)* 65 : 73-77, 2002
  - 29) Hamasu S, Yokoo N, Kitakado Y, Adachi T, Yoshida T, Ura K, Tanaka Y, Nagata H, Okamoto K : Three cases of cancer in the reconstructed gastric tube after radical resection for esophageal cancer, resected by different surgical procedure (in Japanese with English abstract). *Jpn J Gastroenterol Surg (Nihon Shokaki Geka Gakkai Zasshi)* 36 : 186-191, 2003
  - 30) Matsuda K, Fukase K : A case of early cancer of the gastric tube endoscopically resected (in Japanese). *Clinician* 50 : 787-789, 2003
  - 31) Suganuma T, Hase K, Terauchi R, Shikina A, Tanaka M, Aozasa S, Utsunomiya K, Fujino K, Okada K, Tsuda T, Matsukuma S : A case report of multiple early carcinoma arising in reconstructed gastric tube after radical

- operation for esophageal cancer (in Japanese with English abstract). *Jpn J Cancer Clin (Gan no Rinsho)* 50 : 329-333, 2004
- 32) Tanaka M, Yanai H, Matsubara Y, Kitoh T, Nakamura Y, Yoshida T, Okita K : A case of multiple early gastric cancer treated endoscopically in the reconstructed stomach after esophagectomy (in Japanese with English abstract). *Yamaguchi Med J (Yamaguchi Igaku)* 53 : 103-107, 2004
- 33) Motoyama S, Mori K, Maruyama K, Sato Y, Hayashi K, Usami S, Suzuki H, Ogawa J : S-1 chemotherapy for cancer of the gastric tube used for esophageal reconstruction following surgery for esophageal cancer (in Japanese with English abstract). *Jpn J Cancer Chemother (Gan to Kagaku Ryoho)* 34 : 2287-2290, 2007
- 34) Yamasawa K, Shimizu T, Shimosato A, Mihara F, Tokuhara M, Hashimoto M, Saito Y, Endo H, Tamegai Y : Two cases of cancer in the reconstructed gastric tube after resection of esophageal cancer -an analysis of 7 cases in our hospital- (in Japanese with English abstract). *Jpn J Gastroenterol (Nippon Shokakibyo Gakkai Zasshi)* 106 : 793-799, 2009
- 35) Koyanagi K, Kanai T, Nakagawa M, Nagase T, Tawara H, Tabuchi S, Koyama I : Endoscopic treatment for metachronous early gastric carcinoma in a reconstructed gastric tube after radical operation of esophageal carcinoma -summary of 29 reported cases- (in Japanese). *Prog Dig Endosc* 74 : 24-27, 2009
- 36) Suzumura K, Oh K, Imuro Y, Yamanaka J, Kuroda N, Hirano T, Okada T, Uyama N, Satake M, Fujimoto J : A case of gastric tube cancer 4 years after esophagectomy for thoracic esophageal cancer treated by endoscopic mucosal resection (in Japanese with English abstract). *JJSC (Nihon Gekakei Rengo Gakkaishi)* 34 : 582-586, 2009
- (2010. 10. 21 received ; 2010. 12. 13 accepted)
-